



ROYAL AUSTRALASIAN COLLEGE OF SURGEONS

Fellowship Examination 2013

Neurosurgery

Written Paper One

Tuesday 16 April 2013

Reading Time: 10:00am to 10:10am (10 minutes)

Writing Time: 10:10am to 12:10pm (2 hours)

QUESTION BOOK

<i>Section</i>	<i>Number of Questions to be Answered</i>
Essay Questions	3

Candidates are permitted to bring into the examination room:

- Pens
- Pencils
- Erasers

Candidates are not permitted to bring into the examination room:

- Blank sheets of paper
- White-out liquid/tape

Materials supplied:

- Question Book of 4 pages
- Answer Book

Instructions to candidates:

- Write your candidate number on the front of each Answer Book.
- Write your response in the Answer Book provided.
- All answers must be written in English.

At the end of the examination, candidates are to leave the Question Book and Answer Book on their desk.

Candidates are not permitted to remove the Question Book from the examination room.

Candidates are NOT permitted to bring mobile phones and/or any other unauthorised devices into the examination room.

Essay Questions

Write your response in the answer book provided.

Clearly number the question you are answering.

Question 1

A 24 year old man was thrown over the handlebars of his pushbike, his face and forehead striking the curb. Neurological examination revealed he was alert with no focal signs. Selected bony views of his CT scan are shown in Figure 1 and 2.

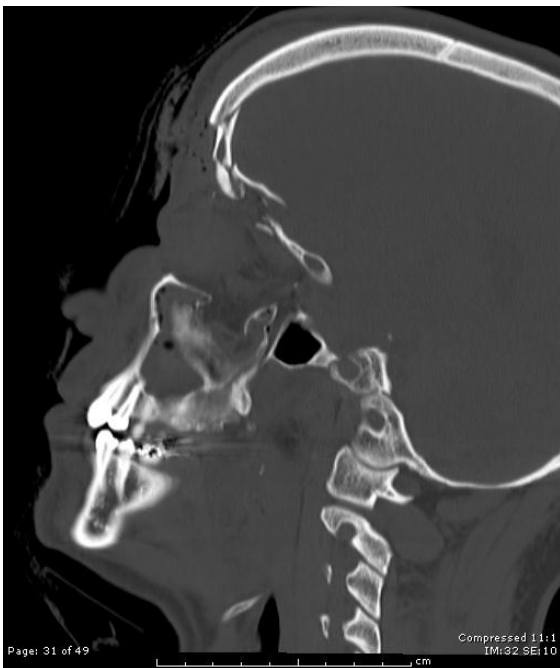


Figure 1

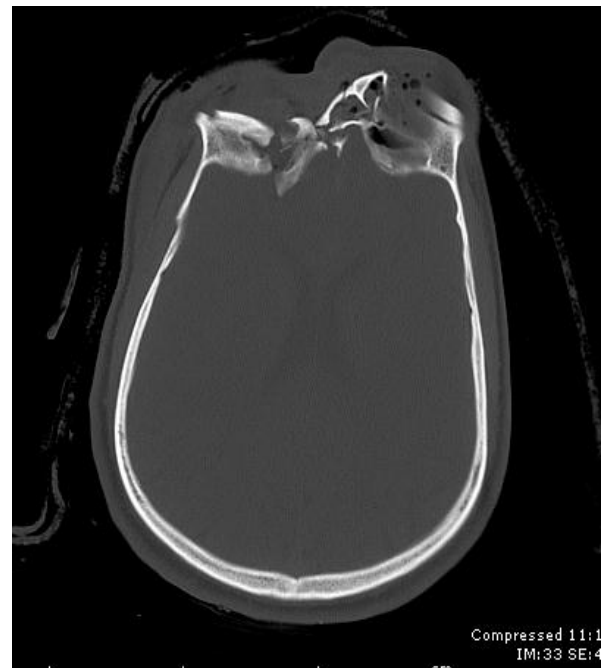

Figure 2

- A. Describe the anatomy of the anterior cranial fossa floor, in your answer include osteology, neuroanatomical structures, and the innervations and blood supply of the anterior cranial fossa
- B. Discuss in detail your initial non-operative and operative management.
- C. One month after the injury, in the rehabilitation ward, he develops a fever and has been noted to have intermittent clear fluid running from his nose. Discuss the investigation and management of the suspected CSF leak and meningitis, including a discussion of open and endoscopic operative repair.

Question 2

An 18 month old child presented with increased irritability, lethargy and vomiting. The mother had noticed that her child was not as active over the last 3 months. Axial T2-weighted and sagittal T1-weighted views of the MRI are shown in Figure 1 and 2.

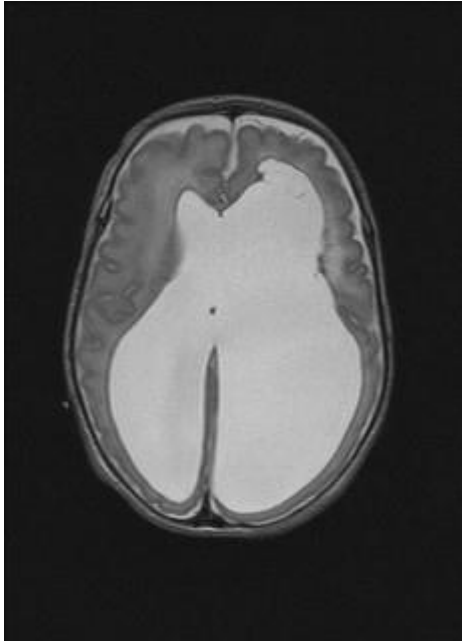


Figure 1

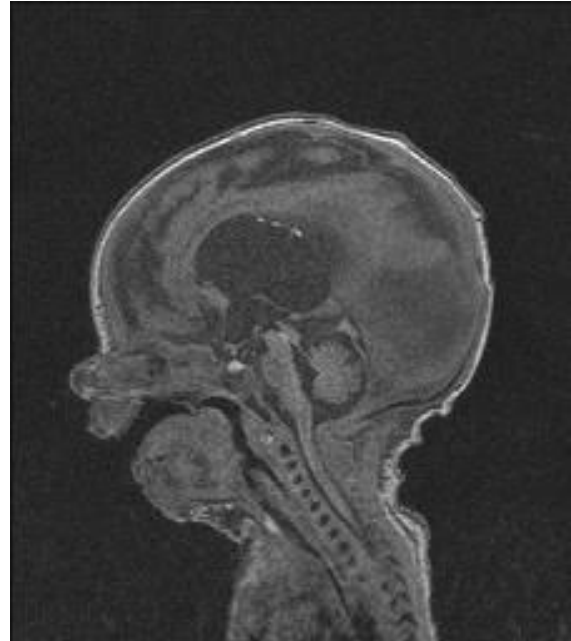


Figure 2

- A. Describe the features of the MRI and discuss the mechanism of the condition.
- B. Discuss the different treatment options.
- C. Outline your discussion with the parents regarding informed consent for the management of their child.
- D. Describe the normal physiology of cerebrospinal fluid production.

Question 3

- A. Describe the anatomy and connections of the basal ganglia. Describe important connections as they relate to the treatment of Parkinson's disease.
- B. Describe the common surgical targets for the treatment of Parkinson's disease and outline the advantages and disadvantages of each target.
- C. Compare and contrast the rationale of ablative and stimulation treatments for Parkinson's disease.



ROYAL AUSTRALASIAN COLLEGE OF SURGEONS

Fellowship Examination 2013

Neurosurgery

Written Paper Two

Tuesday 16 April 2013

Reading Time: 2:00pm to 2:10pm (10 minutes)

Writing Time: 2:10pm to 4:10pm (2 hours)

QUESTION BOOK

<i>Section</i>	<i>Number of Questions to be Answered</i>
One - Essay Questions	2
Two - Short Answer Question	1

Candidates are permitted to bring into the examination room:

- Pens
- Pencils
- Erasers

Candidates are not permitted to bring into the examination room:

- Blank sheets of paper
- White-out liquid/tape

Materials supplied:

- Question Book of 4 pages
- Answer Book

Instructions to candidates:

- Write your candidate number on the front of each Answer Book.
- Write your response in the Answer Book provided.
- All answers must be written in English.

At the end of the examination, candidates are to leave the Question Book and Answer Book on their desk.

Candidates are not permitted to remove the Question Book from the examination room.

Candidates are NOT permitted to bring mobile phones and/or any other unauthorised devices into the examination room.

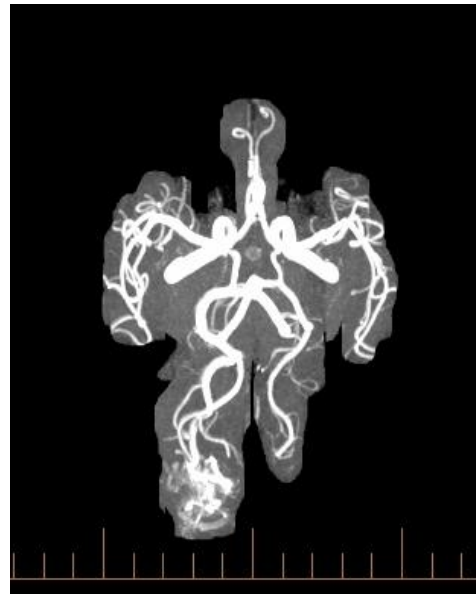
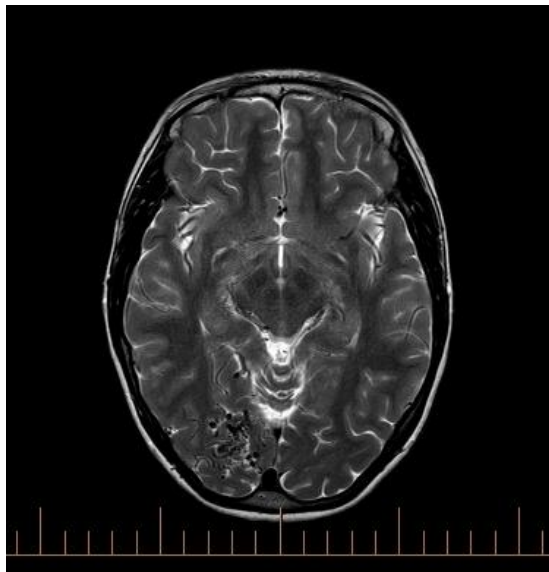
Section One: Essay Question

Write your response in the answer book provided.

Clearly number the question you are answering.

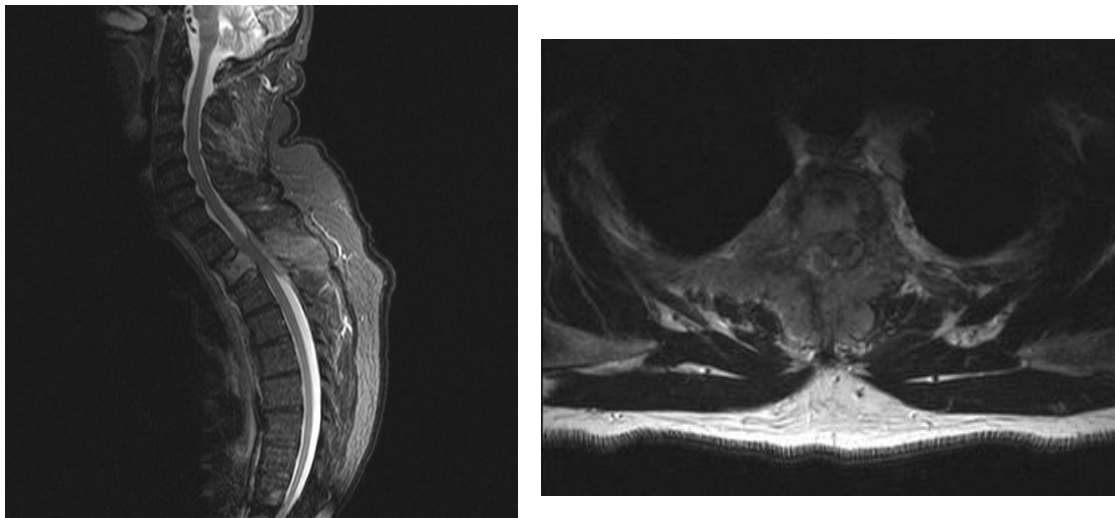
Question 1

A 32 year old right handed woman, who is 32 weeks pregnant, presented with left focal visual seizures. Neurological examination was normal. The pregnancy was proceeding in the normal way. A T2weighted axial MRI and MR angiogram are shown.



- A. Describe the lesion. Outline the anatomy and vascular supply of the occipital lobe.
- B. Outline the Spetzler-Martin grading system and its significance.
- C. Write a letter to the referring obstetrician outlining your management of this patient.
- D. Discuss the angiographic features that may be associated with increased risk of haemorrhage of an AVM.

Question 2



- A. Describe the radiological features of the lesion shown in the MRI above and include the radiological distinguishing features of extra-medullary and intra-medullary lesions in your discuss.
- B. Discuss the important clinical factors that influence your decision to operate on this patient.
- C. Discuss the indications for spinal fixation in patients with metastatic spinal tumours

Section Two - Short Answer Questions

Write your response in the answer book provided.

Clearly number the question you are answering.

Question 3

- A. Discuss the surgical options for the management of an intracerebral abscess.
- B. Outline the medical and surgical management options for hemifacial spasm
- C. Describe the diagnosis and treatment of cerebral salt wasting syndrome
- D. What are the management options for a 1.5cm unilateral acoustic neuroma? Discuss your preferred option and your reasons for choosing it.
- E. Write short notes on Lhermitte-Duclos syndrome.
- F. Discuss the clinical features of ankylosing spondylitis and management of a patient with this condition who has a cervical fracture.