



ROYAL AUSTRALASIAN COLLEGE OF SURGEONS

Fellowship Examination 2017

Neurosurgery

Written Paper One

Friday 18th August 2017

QUESTION & ANSWER BOOK

| <i>Section</i> | <i>Number of Questions to be Answered</i> |
|-----------------|---|
| Essay Questions | 3 |

Candidates are permitted to bring into the examination room:

- Pens
- Pencils
- Erasers

Candidates are not permitted to bring into the examination room:

- Blank sheets of paper
- White-out liquid/tape

Materials supplied:

- Question and Answer Book of 65 pages

Instructions to candidates:

- All answers must be written in English.
- Write only on the lined pages.

At the end of the examination, candidates are to leave the Question and Answer Book on their desk. Candidates are not permitted to remove the Question Book from the examination room.

Candidates are NOT permitted to bring mobile phones and/or any other unauthorised electronic devices into the examination room.

Essay Questions

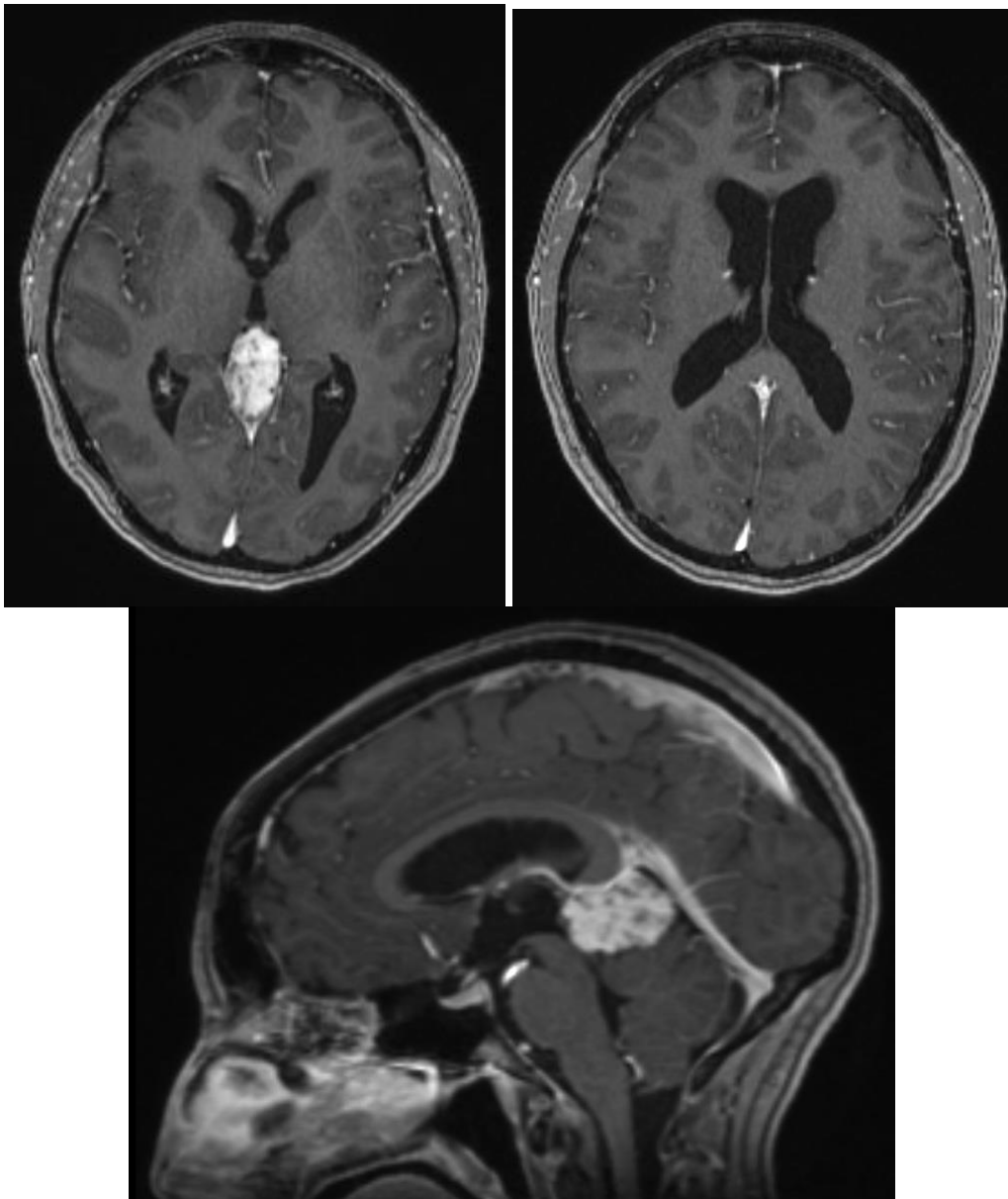
Candidates are to write answers in the space provided. Answers outside this area will not be seen in the Examiners' copies of the answers and will therefore not be assessed.

ALL questions must be answered. Clearly number the sub question you are answering.

Question 1

A 50 year old woman presents with a three month history of headache.

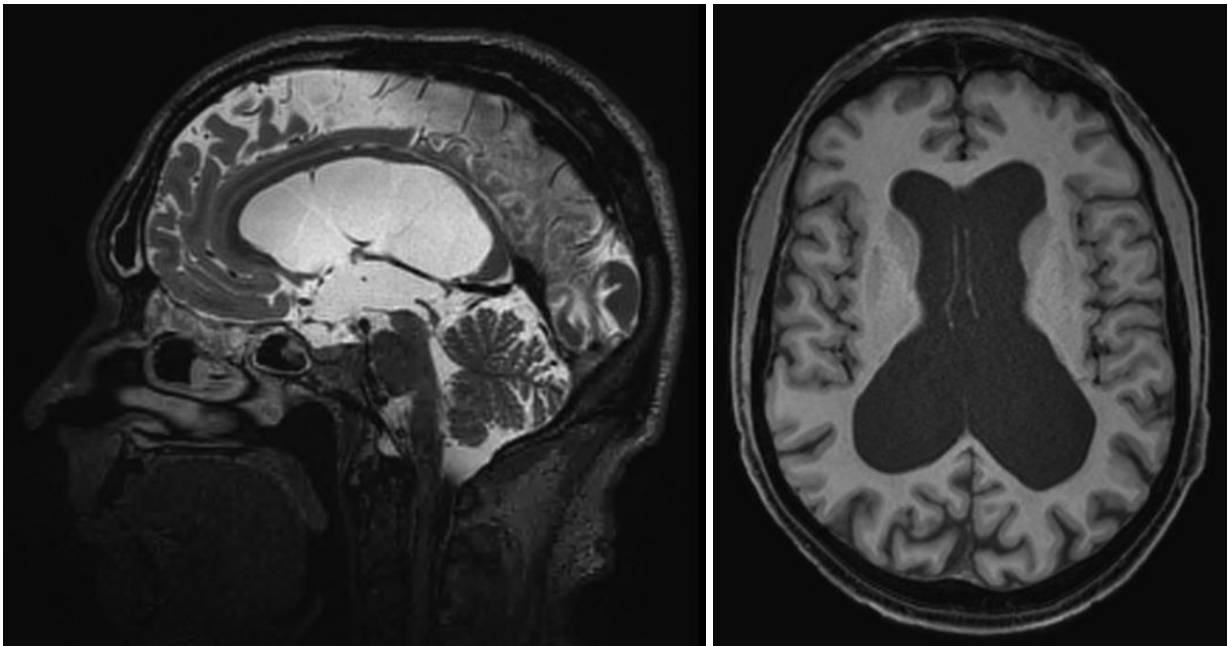
- Describe the radiological findings.
- List the differential diagnoses.
- What further investigations would you consider?
- Describe the various operative approaches for excision of this lesion and outline the reasons for your preferred approach.



Question 2

A 52 year old man presents with a three month history of headaches

- a) Describe the radiological findings.
- b) What specific questions would you ask when taking a history to establish the clinical significance of the MRI findings? What features of the examination are also relevant?
- c) What are the surgical options available? Describe their advantages and disadvantages.

**Question 3**

Describe the origin, course, branches and anatomical relations of the anterior cerebral artery.

Discuss the clinical syndromes that can occur due to occlusion of these vessels.

Describe the common anatomical variations of the anterior cerebral artery.

END OF PAPER



ROYAL AUSTRALASIAN COLLEGE OF SURGEONS

Fellowship Examination 2017

Neurosurgery

Written Paper Two

Friday 18th August 2017

QUESTION & ANSWER BOOK

| <i>Section</i> | <i>Number of Questions to be Answered</i> |
|-----------------------------|---|
| One - Essay Questions | 2 |
| Two - Short Answer Question | 1 |

Candidates are permitted to bring into the examination room:

- Pens
- Pencils
- Erasers

Candidates are not permitted to bring into the examination room:

- Blank sheets of paper
- White-out liquid/tape

Materials supplied:

- Question and Answer Book of 61 pages

Instructions to candidates:

- All answers must be written in English.
- Write only on the lined pages.

At the end of the examination, candidates are to leave the Question and Answer Book on their desk. Candidates are not permitted to remove the Question Book from the examination room.

Candidates are NOT permitted to bring mobile phones and/or any other unauthorised electronic devices into the examination room.

Section One - Essay Questions

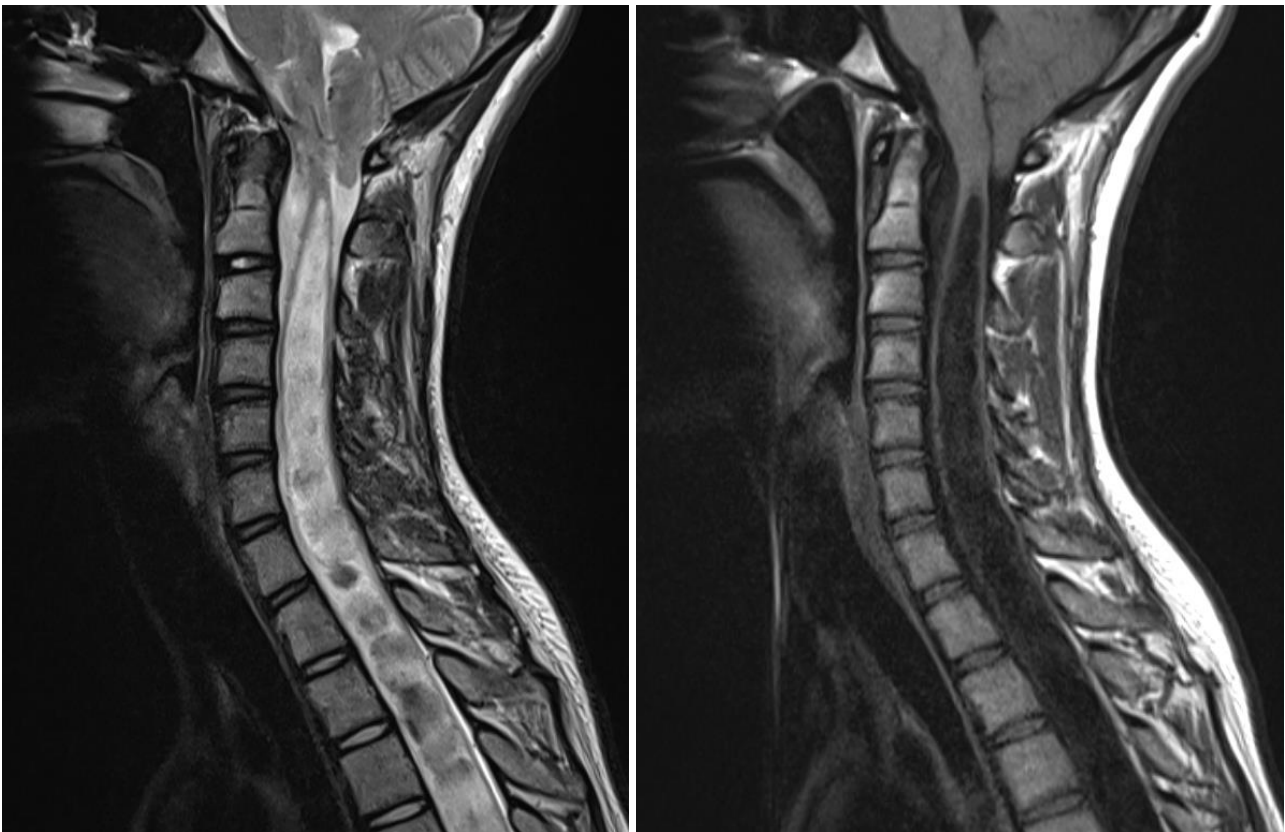
Candidates are to write answers in the space provided. Answers outside this area will not be seen in the Examiners' copies of the answers and will therefore not be assessed.

ALL questions must be answered. Clearly number the sub question you are answering.

Question 1

A 17 year old woman presents with difficulty using her left hand and some unsteadiness. Clinical examination revealed clawing of her left hand, brisk symmetrical reflexes and unsteadiness of gait, such that she was unable to walk heel to toe.

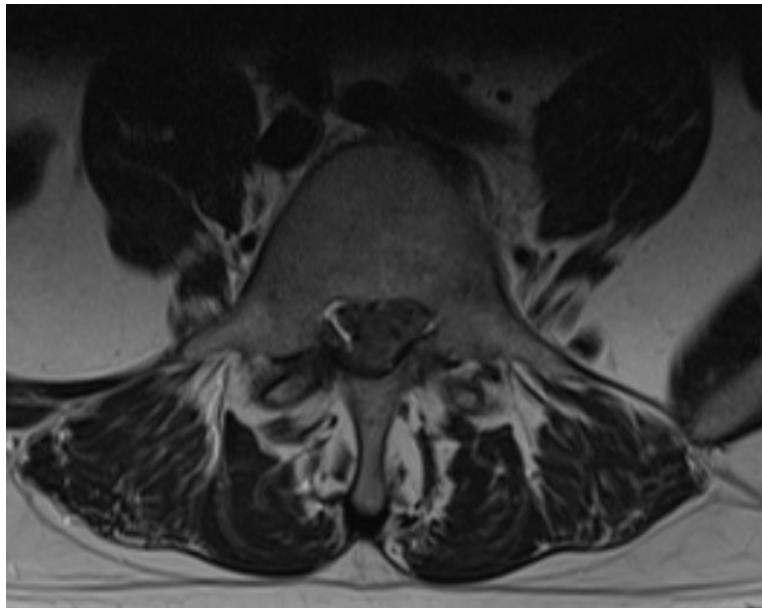
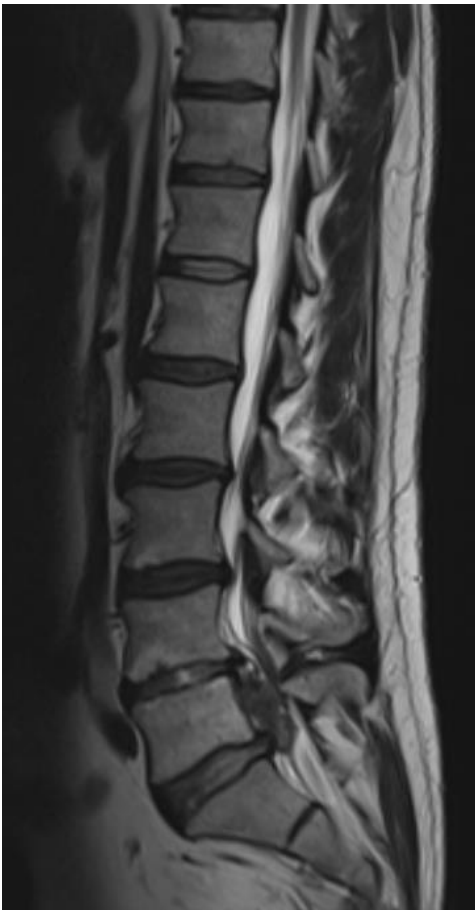- A. Describe the radiological findings.
- B. What are the proposed theories of the pathophysiology of the condition in this patient?
- C. Describe the technical variations of the surgical procedure to treat this condition and their advantages and disadvantages.



Question 2

It is 1 am. A twenty nine year old man presents to the emergency department with acute onset of severe low back pain and bilateral leg pain radiating down the lateral aspect of the calves. An MRI scan of the lumbar spine has been performed and is shown.

- A. Describe the radiological findings. Would you recommend any additional imaging?
- B. Describe features of the history and examination that may influence your management.
- C. Describe the anticipated surgical challenges in performing emergency surgery in this patient. Explain your strategies to manage these challenges.



Section Two – Short Answer Question

Candidates are to write answers in the space provided. Answers outside this area will not be seen in the Examiners' copies of the answers and will therefore not be assessed.

ALL questions must be answered. Clearly number the sub question you are answering.

Question 3

Write short notes on:

- A. The short and long term success rates of microvascular decompression for typical Type 1 trigeminal neuralgia. List the transient and permanent complications after this surgery and their likelihood.
- B. The role of decompressive craniectomy for middle cerebral artery infarction.
- C. List the cranial nerve parasympathetic ganglia and the cranial nerves with which they are associated. Describe their functions.
- D. Describe in detail the common neurological syndrome caused by a mid-humerus fracture.
- E. What anatomical and clinical factors influence your choice of surgical approach to a foraminal L3/4 disc prolapse?

END OF PAPER